

Clinical Presentation of ENPP1 Deficiency

Generalized Arterial Calcification of Infancy Phenotype

Generalized arterial calcification of infancy (GACI) is a rare inherited autosomal recessive disease characterized by severe ectopic mineralization of the arterial vessel system that can be observed in patients in utero or neonatally. The disease is life threatening, and patients that do survive face poor outcomes and lifelong disease management. Homozygous inactivating mutations in the *ENPP1* gene have been reported in as many as 75% of genetically tested patients (GACI Type 1), suggesting low levels of PPI, an inhibitor of calcification in this disease.

INTRODUCTION

The *ENPP1* gene produces a key enzyme responsible for the production of extracellular, inorganic pyrophosphate, a potent inhibitor of mineralization. The associated decrease in serum pyrophosphate due to loss of function of the ENPP1 protein, is responsible for ectopic, pathogenic mineralization of the arteries. GACI can also be caused by biallelic mutations within the *ABCC6* gene (GACI Type 2), which is a member of the multidrug resistance superfamily. Mutations in the *ABCC6* gene have also been linked to decreased levels of serum pyrophosphate in murine models and in patients.

Although the exact prevalence of GACI is unknown, based on an estimated carrier frequency of 1 in 312 people, the disease frequency is predicted to be about 1 in 200,000 individuals. Inheritance appears to occur without either gender or ethnic predilection.

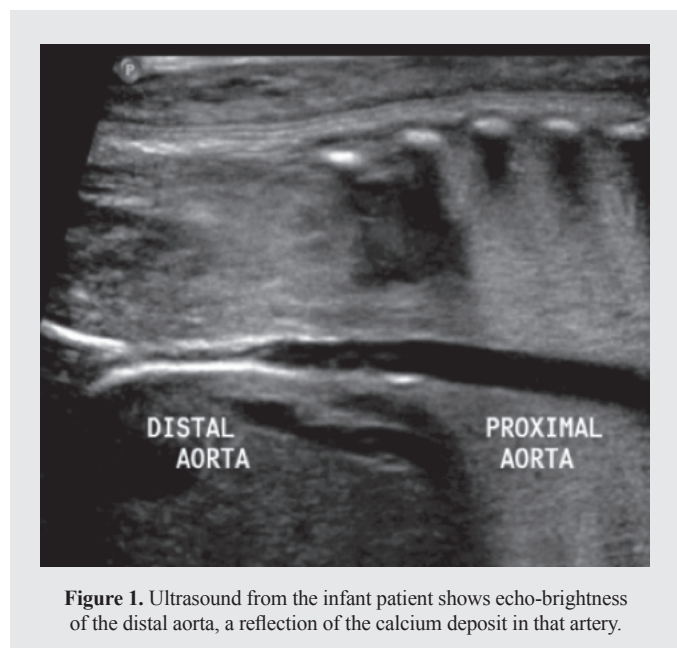
GACI is diagnosed through a combination of clinical, imaging or histopathological findings and confirmed by genetic testing to evaluate for mutations in either the *ENPP1* or *ABCC6* genes. The disease is characterized visually by ultrasonography or computed tomography scans showing prenatal or infantile widespread calcification of large- and medium-sized arteries. Early diagnosis by amniocentesis is possible if mutations of *ENPP1* or *ABCC6* have previously been detected within other family members.

Severe calcification of the internal elastic lamina, fibrotic myointimal proliferation within arteries, reduced vascular elasticity, and resultant arterial stenosis are characteristic of the disorder. This leads to hypertension, myocardial ischemia, and heart failure. Affected vessels typically include the aorta, coronary, pulmonary, and renal arteries. These calcifications can typically lead to the death of patients before 6 months of age, despite intensive care therapy and ventilatory support. Deaths have been attributed to congestive heart failure, persistent arterial hypertension, multiorgan failure or myocardial infarction. Initial reports of confirmed GACI patients have suggested a mortality rate of up to 85% by 12 months of age. Treatment using bisphosphonates, a pyrophosphate analog, have been used with mixed results.

Clinically, GACI presents with respiratory distress, systemic hypertension, congestive heart failure, cyanosis, and cardiomegaly. Other, more widespread signs and symptoms may occur if patients survive beyond 12 months; these include calcification of the joints, hearing loss, and the softening of bones associated with rickets. This phenotype of ENPP1 deficiency, called ARHR2, manifests with low levels of circulating phosphate. Histological findings on autopsy of GACI infants have also demonstrated calcification in renal tissue, specifically the glomerular tufts, parietal portion of Bowman's capsule, and renal tubules.

PATIENT PROFILE CASE STUDY

A 3-month-old male infant presented with severe early-onset hypertension refractory to therapy. The infant exhibited respiratory distress, cyanosis, refusal to feed, vomiting, and irritability. Further investigation was undertaken via a renal Doppler ultrasound of the distal aorta, revealing the presence of diffuse echo-brightness characteristic of calcified arteries (Figure 1).



Subsequently, a low-dose whole-body computed tomography (CT) scan was performed, which demonstrated the existence of extensive calcifications (Figure 2). The scan revealed that there was increased density of the arterial walls at several sites, including the aorta and costal, iliac, tibial, and ulnar arteries. In addition, slight periarticular calcification of the right hip was observed.

Family history revealed the patient had a twin sister with similar, yet more severe, symptomatology who did not survive beyond 2 months of age. Autopsy results revealed that her death was due to congestive heart failure and cardiomegaly. Due to the severe arterial calcification noted in the histopathologic investigation at the time of her autopsy (Figure 3), a diagnosis of GACI was considered for both siblings. DNA was extracted

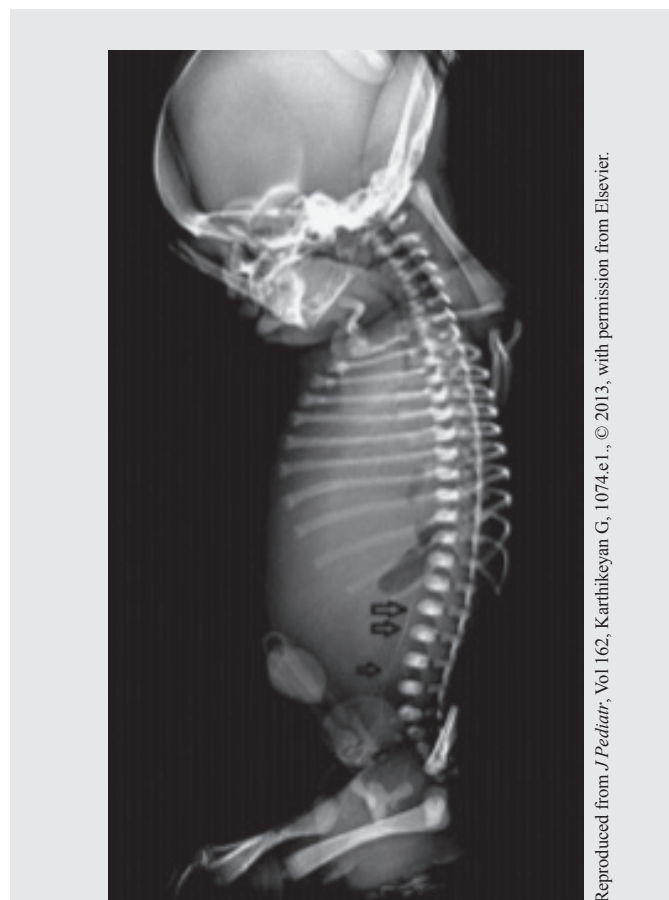

Figure 2. Lateral radiograph of the neonate showing calcification of descending aorta and its bifurcation (arrows).

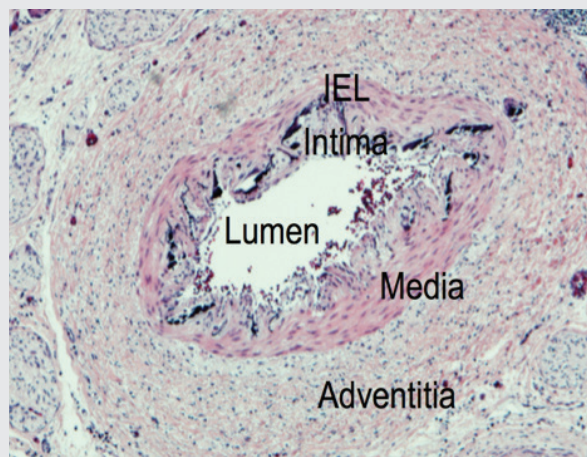


Figure 3. The patient's twin sister died at 3 months of age, prior to GACI diagnosis. Pathology analysis and histochemical staining revealed calcification of the internal elastic lamina (IEL) (shown in purple) of the female infant's aorta.

from the male infant's blood and *ENPP1* gene analysis was performed. DNA sequence analysis detected a previously identified homozygous mutation in the *ENPP1* gene.

DISCUSSION













The association of the inactivation of the ENPP1 protein with decreased levels of serum pyrophosphate provide a mechanism to understand the development of the observed aberrant calcification in GACI patients. This has led to greater insight into understanding the role of pyrophosphate in preventing ectopic, pathogenic calcifications in GACI as well as in other disease states.

Advances have been made in recognizing inherited single-gene disorders through utilization of prenatal diagnostics and carrier screening, where rapid methodological developments are taking place. Early diagnosis, neonatally or in utero, via detection of aortic calcifications on ultrasound in conjunction with genetic testing should facilitate better management of patients afflicted with GACI.

SUMMARY

- The ENPP1 enzyme is responsible for the production of extracellular, inorganic pyrophosphate, a potent inhibitor of mineralization. Deficiency of this enzyme causes decreased levels of serum pyrophosphate, which leads to the calcification of large- and medium-sized arteries.
- In as many as 75% of genetically tested GACI patients, homozygous, inactivating mutations in the *ENPP1* gene have been reported; in a small percentage of patients, biallelic mutations in *ABCC6* have also been observed.
- Mutations in the *ENPP1* and *ABCC6* genes are associated with decreased levels of serum pyrophosphate in patients and can manifest as distinct disorders with overlapping phenotypic symptoms (Table 1), suggesting that the protein products of both of these genes are involved in the regulation of the same metabolic pathway.
- Early identification via genetic testing/screening should lead to improved outcomes for many more patients afflicted with rare diseases such as GACI.

Table 1. Spectrum of symptoms associated with ENPP1 and ABCC6 mutations

	Infancy		Childhood			
GACI Type I (ENPP1 Associated)	 Arterial Calcification	 Myocardial Ischemia	 Joint Calcification	 Hypophosphatemic Rickets	 Nephrocalcinosis	 Hearing Loss
GACI Type II (ABCC6 Associated)	 Arterial Calcification	 Myocardial Ischemia	 Joint Calcification	 Hypophosphatemic Rickets	 Nephrocalcinosis	 Hearing Loss

Mutations of either *ENPP1* or *ABCC6* can cause the severe phenotype of generalized arterial calcification of infancy, which frequently leads to death within the first year of life. Individuals who survive the critical period during infancy may develop rickets, nephrocalcinosis, and hearing loss.

INOZYME GENETIC TESTING PROGRAM

Inozyme Pharma is partnering with PreventionGenetics to offer a no-cost genetic testing program to improve the detection and understanding of the rare calcification disorder GACI (generalized arterial calcification of infancy). Offered globally, the program tests for mutations in the *ENPP1* and *ABCC6* genes, which are implicated in this severe calcification disorder. The genetic test can identify individuals who may have the condition or are carriers for the *ENPP1* or *ABCC6* deficiency.

For additional information, please contact **PreventionGenetics** at **1-715-387-0484** and/or mail
clinicaldnatesting@preventiongenetics.com

OR

visit **<https://www.preventiongenetics.com/specialOrders?sp=sp051>**

REFERENCES

- Albright RA, Stabach P, Cao W, et al. ENPP1-Fc prevents mortality and vascular calcifications in rodent model of generalized arterial calcification of infancy. *Nat Commun*. 2015 Dec 1; 6:10006. doi: 10.1038/ncomms10006.
- Brachet C, Mansbach AL, Clerckx A, et al. Hearing loss is part of clinical picture of ENPP1 loss of function mutation. *Horm Res Paediatr*. 2014;81:63-6.
- Chong CR, Hutchins GM. Idiopathic infantile arterial calcification: the spectrum of clinical presentations. *Pediatr Dev Pathol*. 2008;11(5):405-15.
- De Vilder EY, Vanakker OM. From variome to phenome: pathogenesis, diagnosis and management of ectopic mineralization disorders. *World J Clin Cases*. 2015;3(7):556-74.
- Ferreira C, Ziegler S, Gahl WA. Generalized arterial calcification of infancy. In: Adam MP, Ardinger HH, Pagon RA, et al, eds. *GeneReviews* [Internet]. Seattle, WA: University of Washington, Seattle; 1993-2019. <https://www.ncbi.nlm.nih.gov/books/NBK253403/>. Published November 13, 2014. Accessed November 8, 2019.
- Genetic testing program. Inozyme Pharma website. <https://www.inozyme.com/patients-hcps/genetic-testing-program/>. Accessed November 8, 2019.
- Khan T, Sinkevicius KW, Vong S, et al. ENPP1 enzyme replacement therapy improves blood pressure and cardiovascular function in a mouse model of generalized arterial calcification of infancy. *Dis Model Mech*. 2018 Oct 8;11(10). pii: dmm035691. doi: 10.1242/dmm.035691.
- Moran JJ. Idiopathic arterial calcification of infancy: a clinicopathologic study. *Pathol Annu*. 1975;10:393-417.
- Nitschke Y, Baujat G, Botschen U, et al. Generalized arterial calcification of infancy and pseudoxanthoma elasticum can be caused by mutations in either ENPP1 or ABCC6. *Am J Hum Genet*. 2012;90(1):25-39.
- Orriss IR, Arnett TR, Russell RG. Pyrophosphate: a key inhibitor of mineralisation. *Curr Opin Pharmacol*. 2016;28:57-68.
- Rashdan NA, Rutsch F, Kempf H, et al. New perspectives on rare connective tissue calcifying diseases. *Curr Opin Pharmacol*. 2016;28:14-23.
- Rutsch F, Böyer P, Nitschke Y, et al. Hypophosphatemia, hyperphosphaturia, and bisphosphonate treatment are associated with survival beyond infancy in generalized arterial calcification of infancy. *Circ Cardiovasc Genet*. 2008;1(2):133-40.
- Rutsch F, Vaingankar S, Johnson K, et al. PC-1 nucleoside triphosphate pyrophosphohydrolase deficiency in idiopathic infantile arterial calcification. *Am J Pathol*. 2001;158(2):543-54.
- Spear R, Mack LA, Benedetti TJ, et al. Idiopathic infantile arterial calcification. In utero diagnosis. *J Ultrasound Med*. 1990;9(8):473-6.
- Steichen-Gersdorf E, Lorenz-Depiereux B, Strom TM, et al. Early onset hearing loss in autosomal recessive hypophosphatemic rickets caused by loss of function mutation in ENPP1. *J Pediatr Endocrinol Metab*. 2015;28(7-8):967-70.
- What is GACI? GACI Global website. <https://gaciglobal.org/medical-information/what-is-gaci/>. Accessed November 1, 2019.
- Ziegler SG, Gahl WA, Ferreira CR. Disorders and mechanisms of ectopic calcification. In: Thakker RV, Whyte MP, Eisman JA, et al, eds. *Genetics of Bone Biology and Skeletal Disease*. 2nd ed. London, United Kingdom: Elsevier, Inc; 2018:571-95.